

Patient Information

Patient ID: 123-45-6789
Patient Name: Michelle L. Roddy
Date of Birth: 04-Mar-1963
Gender: Female
Submission Date: 2019/03/15 12:17

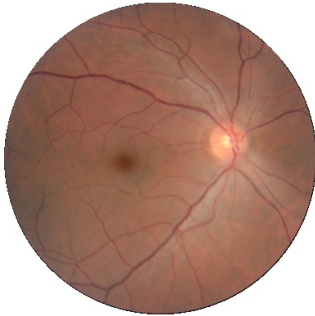General Information

Referring Location: St. Lucy's
Referring Provider: Dr. Charlie Hallock
Encounter ID: 0987-abc-d1c
Eyenuk Control ID: 560142
Dilation Status: Non Dilated

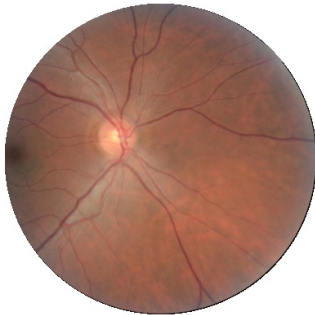Diabetic Retinopathy Screening Summary

Screening Result: Negative for referable diabetic retinopathy.

Right Eye: No apparent DR [0]

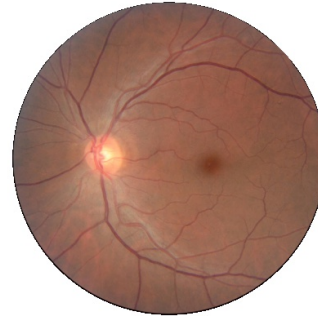


Macula Centered

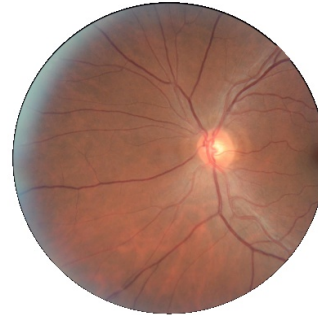


ONH Centered

Left Eye: No apparent DR [0]



Macula Centered



ONH Centered

*Do not use the above thumbnail images for diagnostic purposes.

ICD-10 Diagnosis Codes

E11.9 Type 2 diabetes mellitus without complications

Plan and Recommendations

Return for retinal imaging within 12 months.

As per ADA recommendations, emphasize the importance of controlling blood sugar, cholesterol and blood pressure as well the importance of routine follow-up with an ophthalmologist regardless of whether visual symptoms are present or absent.

Additional Comments

Left Eye: None

Right Eye: None



Digitally signed by Dr. Lauren Davis (License # CA 542-3467-52)

Report Date: 2019/03/15 12:25

Patient Information

Patient ID: 123-45-6791
Patient Name: Benny S. Jones
Date of Birth: 22-Nov-1951
Gender: Male
Submission Date: 2019/03/15 12:21

General Information

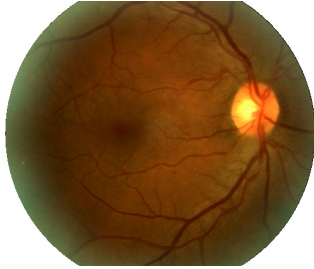
Referring Location: St. Lucy's
Referring Provider: Dr. Charlie Hallock
Encounter ID: 0987-abc-d1f
Eyenuk Control ID: 560143
Dilation Status: Non Dilated

Diabetic Retinopathy Screening Summary

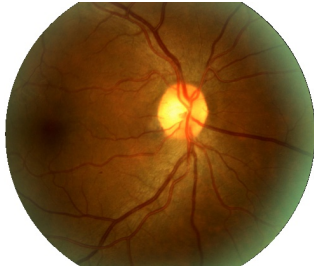Screening Result: Positive for vision threatening diabetic retinopathy.

Right Eye: Moderate NPDR [2] without macular edema

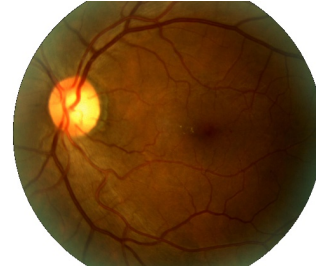
Left Eye: Moderate NPDR [2] with macular edema



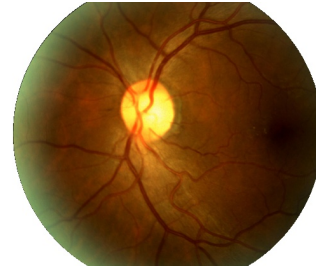Macula Centered



ONH Centered



Macula Centered



ONH Centered

*Do not use the above thumbnail images for diagnostic purposes.

ICD-10 Diagnosis Codes

- E11.3391** Type 2 diabetes mellitus with moderate nonproliferative diabetic retinopathy without macular edema, right eye
- E11.3312** Type 2 diabetes mellitus with moderate nonproliferative diabetic retinopathy with macular edema, left eye

Plan and Recommendations

Immediate referral to ophthalmologist for evaluation of vision threatening diabetic retinopathy.

As per ADA recommendations, emphasize the importance of controlling blood sugar, cholesterol and blood pressure as well the importance of routine follow-up with an ophthalmologist regardless of whether visual symptoms are present or absent.

Additional Comments

Left Eye: None
Right Eye: None



Digitally signed by Dr. Lauren Davis (License # CA 542-3467-52)
Report Date: 2019/03/15 12:26